

Dextrocardia with Situs Solitus in a Nigerian Cadaver: A Case Report

¹Ezejindu D.N., ²Ukoha Ukoha, ³Asomugha A.L, ⁴Udemezue O.O.
^{1,2,3,4}Department of Anatomy, College of Health Sciences, Nnamdi Azikiwe University, Nnewi.

ABSTRACT

This report describes an adult male cadaver with dextrocardia and situs solitus in a Nigerian cadaver. The photographic illustrations revealed a flattened heart that was flipped to the right thus, transposing the great vessels. The report showed that dextrocardia exists amongst Nigerians and possibly Africans and therefore wish to recommend early medical examination since patients with this condition are unaware of their unusual anatomy until they seek medical attention for an unrelated condition. Early detection may lead to a successful surgical management and consequently offer a safer chance of survival since individuals with this unique variation are more prone to congenital cardiac abnormalities.

Date of Submission: 11 July, 2013



Date of Publication: 22 July 2013

I. INTRODUCTION

BACKGROUND

Dextrocardia is an abnormal congenital positioning of the heart. Instead of the heart forming in the fetus on the left side, it flips over and forms on the right side[1]. Dextrocardia is frequently diagnosed in a routine prenatal sonogram, although not every radiologist will catch it, particularly if there are no cardiac structural abnormalities. There are several types of dextrocardia, also called looping defects. It is pertinent to note that people with this anomaly have higher chances of suffering from other problems of the heart especially if other organs are affected also.[2], as seen in a case study by Nawaz et al in their case report which they discovered that the stomach and spleen were located on the right side, while the liver was on the left side, the gallbladder was located in the epigastric area toward the left side. Diagnostic modalities like a chest radiograph and an electrocardiogram are sufficient to make a diagnosis of dextrocardia while more recent imaging modalities like echocardiography and magnetic resonance imaging puts the diagnosis beyond doubt.[4]. We will discuss a case of dextrocardia without accompanying alteration of the abdominal visceral organs.

1.1.CASE REPORT

During a routine supervision of dissection of formalin-fixed adult cadavers by 200 level medical students at College Of Health Sciences Nnamdi Azikiwe University, Nnewi, Nigeria, dextrocardia was observed in one of the male cadavers. A total of 20(18 males and 2 females) cadavers were dissected (during the thorax class) as part of the medical training in Human Anatomy. Our observation became interesting as it provided an avenue for the students to better understand and appreciate the lecture on anatomy of the thorax well. The students were so lucky to have come across such anomaly during their medical training bearing in mind that the condition is a very rare one and most medical students often time do not get to see it throughout their medical training. In our case report; the stomach and spleen were seen in their normal position on the left and the liver on the right. The heart is somewhat flattened and flipped towards the right with its cardiac apex facing the right. This type of dextrocardia is known as Dextrocardia with Situs Solitus or Isolated Dextrocardia where there is transposition of the heart without accompanying alteration of the abdominal viscera unlike that seen in mirror-image dextrocardia with situs inversus where the abdominal visceral organs are altered in position.

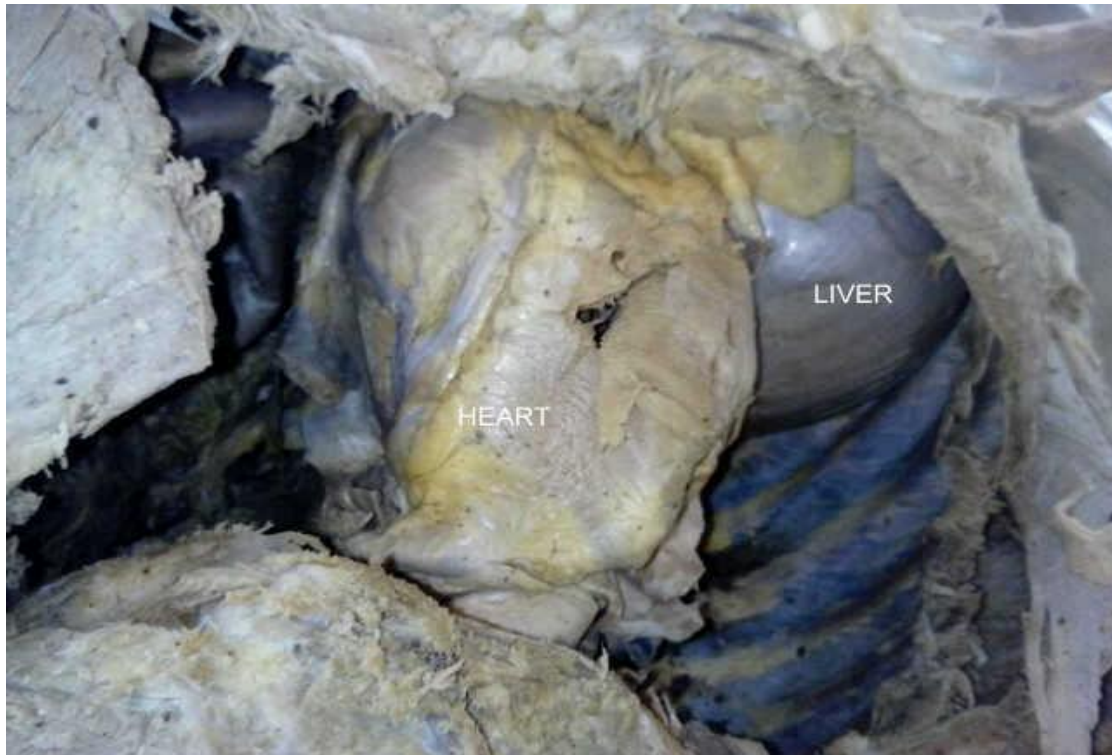


Fig. 1. Superior view of the thoracic cavity in situ. Note the transposition of the heart.

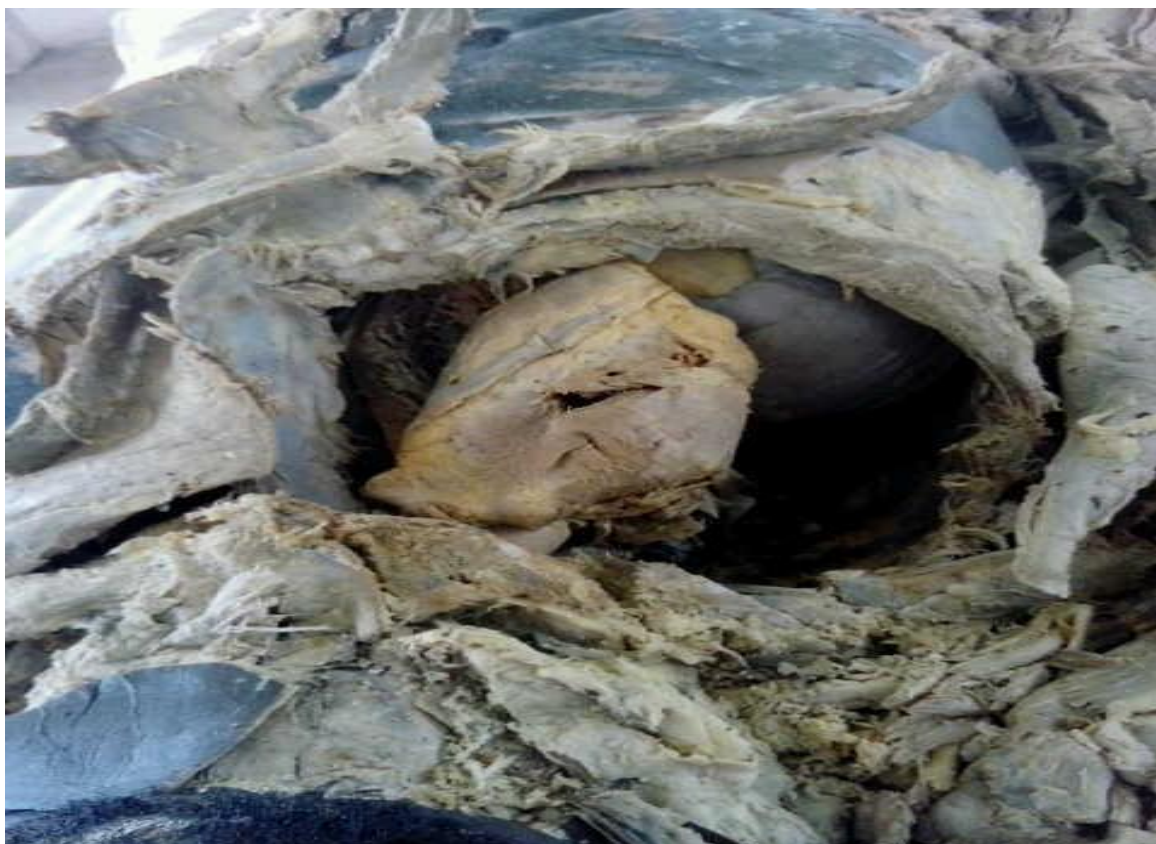

Fig. 2. Superior view of the thoracic cavity in situ. Note the superior aspect of the right lobe of the liver.

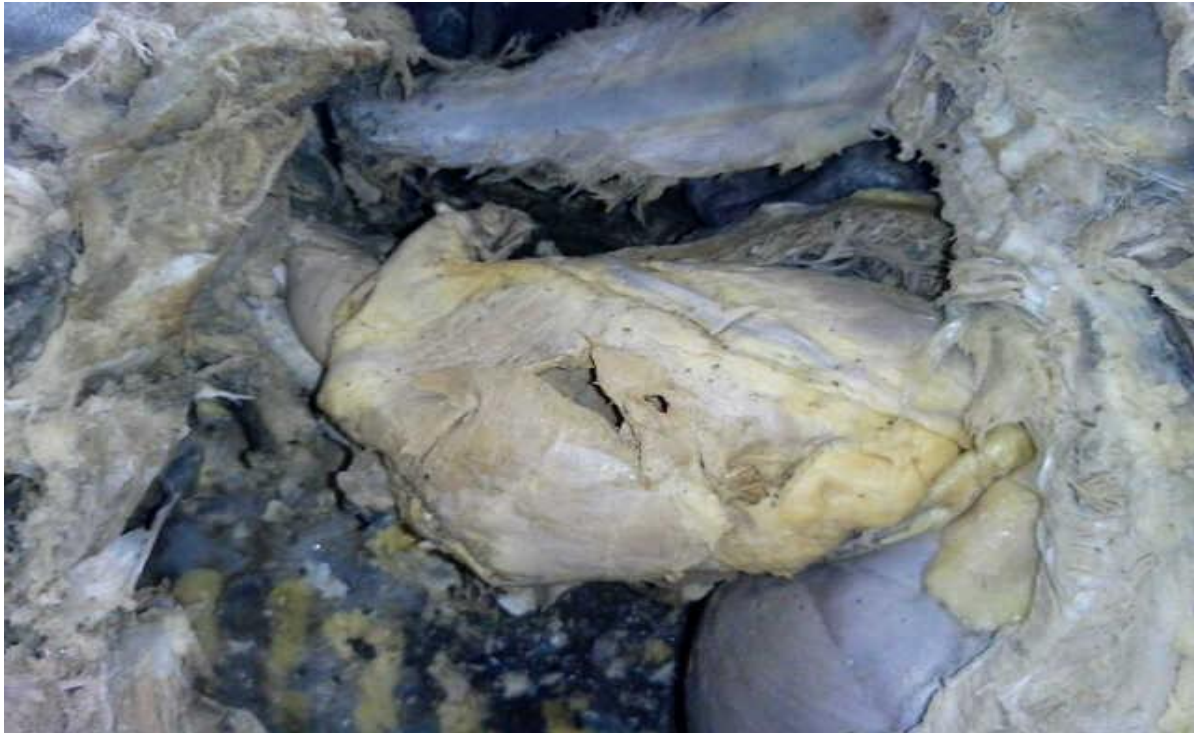

Fig. 3. Lateral view of the thoracic cavity in situ. Showing the heart and part of the liver.

II. DISCUSSION

The term 'dextrocardia' has generated a lot of debate. Dextrocardia occurs in about 0.01% of live births[5]. Though the exact cause is unknown, dextrocardia has been linked with a number of factors including autosomal recessive gene with incomplete penetrance, maternal diabetes, cocaine use and conjoined twinning[6,7]. The arrangements of the position of the abdominal viscera in dextrocardia may be normal (situs solitus), reversed (situs inversus), and indeterminate (situs ambiguous or isomerism) in 32-35%, 35-39% and 26-28% of cases respectively[8]. Incidence of Dextrocardia with Situs Solitus is less common and occurs in 1 per 20,000 live births and the incidence of heart disease is extremely high among this group—about 90% or even greater[9]. Dextrocardia with a normal abdominal situs has a high incidence of associated congenital cardiac anomalies including among others, transposition of the great vessels and atrial[10] and ventricular septal defects[11] in 90-95% of cases. Many people with situs solitus dextrocardia are unaware of their unusual anatomy until they seek medical attention for an unrelated condition. Calvin et al in his work discovered dextrocardia with situs solitus in a 3-year-old boy presented with a chest infection. The computed tomography with 3-dimensional reconstruction also showed aortic coarctation just distal to the origin of the left subclavian artery, left-sided superior vena cava and intralobar sequestration of the right lower lobe. In our case report, we observed a male cadaver with situs solitus dextrocardia. It is important to note that there are higher probability of individuals in this group to suffer congenital cardiac anomalies than the other types of dextrocardia. Often it is diagnosed during a medical examination or during a routine visit to hospital when cardiac function is examined or even during surgery involving other organs other than heart. Surgery in such cases is rendered difficult by the unfamiliarity of the surgeon with such an orientation of the heart. It is very dangerous if this condition is not diagnosed prior to surgery.

III. CONCLUSION

Surgeons, radiologists and radiographers should look out for this anomaly during preoperative and surgical management of their patients. Doctors should encourage routine medical examination for their patients which could help identify this anomaly, thereby preventing wrong diagnosis. For instance, when a patient is having a cardiac pain on the right part of the thorax, it might be waved off as a non-cardiac problem since the heart is thought to be on the left.

IV. ACKNOWLEDGEMENT

The authors appreciate the academic and technical staff of the Department Of Anatomy, College Of Health Sciences, Nnamdi Azikiwe University, Nnewi headed by Dr Ukoha Ukoha

REFERENCES

- [1] Tabry, I. F.; Calabrese, J.; Zammar, H.; AbouKasem, K.; Akeilan, H.; Gharbieh, N.; Zinati, H.; Noureddine, W.; elHout, A.; Tayah, M.; Khalidy, L. & Yaghi, M; 2001. Case Report: Off-Pump Total Myocardial Revascularization for Dextrocardia and Situs Inversus. *Heart Surg. Forum*, 4(3):251-3.
- [2] Ofusori DA, Okwuonu CU, Ude RA, Adesanya OA; 2009. Dextrocardia and situs inversus totalis in a Nigerian cadaver: A case report of rare anomaly. *Int J Morphol*; 27(3): 837-840.
- [3] Nawaz, H.; Matta, M.; Hamchou, A. & Jacobez, A. H. A. Salem; 2005. Situs inversus abdominus in association with congenital duodenal obstruction: a report of two cases and review of the literature. *Pediatr. Surg. Int.*, 21:589-92..
- [4] Uchenna DI, Jesuorobo DE, Anyalechi JI; 2012. Dextrocardia with Situs Inversus Totalis in an Adult Nigerian: a case report, department of Internal Medicine, University of Port Harcourt Teaching Hospital, Port Harcourt, Nigeria.
- [5] Evans WN, Acherman RJ, Collazos JC, Castillo WJ, Rollins RC, Kip KT et al; 2010. Dextrocardia: practical clinical points and comments on terminology. *Pediatr Cardiol*; 31:1-6.
- [6] Agirbashi M, Hamid R, Jennings HS, Tiller GE; 2000. Situs inversus and hypertrophic cardiomyopathy in identical twins; *Am J Genetics*; 91:327-330.
- [7] Distefano G, Romeo MG, Grasso S, Mazonne D, Sciacca P, Mollica F; 1987. Dextrocardia with and without situs viscerum in 2 siblings. *Am J. Med.* 27:929-934
- [8] Isezuo SA, Ma'aji SM, Isah U, Makusidi A; 2010. Dextrocardia with situs viscerum inversus totalis in a 65 year old man: A case report. *Nig Jour Clin Pract.*; 13(1):98-100.
- [9] Roodpeyma SH, Abrarashi M; 1999. Dextrocardia in children of pediatrics; 9(1):41-47.
- [10] Iino K, Watanabe G, Ishikawa N, Tomita S; 2011. Total endoscopic robotic atrial septal defect repair in a patient with dextrocardia and situs inversus totalis; 2011. *Interact Cardio Vasc Thorac Surg*; 0:1-2.
- [11] Piryani RM, Shukla A, Prasad DN, Kohli SC, Shrestha G, Singh D; 2007. Situs inversus with dextrocardia with multiple cardiac lesions in adult. *Kathmandu University Medical Journal*; 5(2):247-249.
- [12] Ng Calvin SH; Wong, Randolph HL; Wan, Innes YP; Underwood, Malcolm J; 2011. Situs Solitus Dextrocardia, Coarctation, Left Superior Vena Cava, Sequestration. *Asian Cardiovascular and Thoracic Annals*, Vol 9(3-4):287.